

Journal of

CONTINUING DENTAL
EDUCATION

UKRAINIAN PUBLIC SCIENTIFIC SOCIETY

Volume 2 • Issue 2 • October 2023

U D J

Ukrainian Dental Journal

У К Р А Ї Н С Ь К И Й
С Т О М А Т О Л О Г І Ч Н И Й
Ж У Р Н А Л

Editor-in-Chief

Larysa Dakhno
Institute of Dentistry, Shupyk National Medical Academy of
Postgraduate Education, Kyiv, Ukraine
Central Laboratory diagnosis of the head, Kyiv, Ukraine

Associate Editors

Myroslav Goncharuk-Khomyn
Uzhhorod National University, Uzhhorod, Ukraine

Editorial board.

Nataliia Bidenko, Kyiv, Ukraine
Michele Callea, Florence, Italy
Lyubov Smaglyuk, Poltava, Ukraine
Kostiantyn Lykhota, Kyiv, Ukraine
Hanna Vyshnevskya, Odesa, Ukraine
Özkan Adıgüzel, Diyarbakır, Turkey
Roberto Fornara, Milano, Italy
Yasemin Yavuz, Sanliurfa, Turkey
Antonino Morabito, Florence, Italy
Iryna Logvynenko, Kyiv, Ukraine
Yaroslav Shkorbotun, Kyiv, Ukraine

Art Designer

Yaroslava Biruk, Kyiv, Ukraine

Founder and Publisher

Ukrainian Public Scientific Society "Continuing Dental Education"
Address: 15, Kyrylivska str., Kyiv, 04080, Ukraine
E-mail: editor.udj@gmail.com
Website: www.journal.dental.ua

Certificate of State Registration of Print Media

Series KB № 25041 - 14981P from 30.11.2021

Certificate of making a publishing house subject to the State Register of publishers, manufacturers and distributors of publishing products

Series ДК №7617 from 01.06.2022
Ukrainian Dental Journal (**p-ISSN** 2786-6297; **e-ISSN** 2786-6572)
is official Journal of the Ukrainian Public Scientific Society for
Continuing Dental Education

DOI: 10.56569

Published: from the year 2021

Frequency: semiannual (March, October)

Manuscript Languages: English, Ukrainian

Ukrainian Dental Journal accepts articles for Open Access publication

UDC: 616.314(477)(05)

Головний редактор

Лариса Дахно
Інститут стоматології Національного університету охорони
здоров'я України імені П. Л. Шупика, Київ, Україна
Central Laboratory diagnosis of the head, Київ, Україна

Заступник головного редактора

Мирослав Гончарук-Хомин
Ужгородський національний університет, Ужгород, Україна

Редколегія

Наталія Біденко, Київ, Україна
Мікеле Каллеа, Флоренція, Італія
Любов Смаглюк, Полтава, Україна
Костянтин Лихота, Київ, Україна
Ганна Вишневська, Одеса, Україна
Озкан Адігузель, Діярбакир, Туреччина
Роберто Форнара, Мілан, Італія
Ясемін Явуз, Шанлиурфа, Туреччина
Антоніно Морабіто, Флоренція, Італія
Ірина Логвиненко, Київ, Україна
Ярослав Шкорботун, Київ, Україна

Дизайн та верстка

Ярослава Бірюк, Київ, Україна

Засновник і Видавець

ГС "Безперервного професійного розвитку стоматологів"
Адреса: 04080, Україна, м. Київ, вул. Кирилівська, 15
Електронна адреса: editor.udj@gmail.com
Веб-сайт: www.journal.dental.ua

Свідоцтво про державну реєстрацію друкованого ЗМІ

Серія KB № 25041 - 14981P від 30.11.2021

Свідоцтво про внесення суб'єкта видавничої справи до Державного реєстру видавців, виготовлювачів і розповсюджувачів видавничої продукції

Серія ДК №7617 від 01.06.2022
Український стоматологічний журнал (**p-ISSN** 2786-6297; **e-ISSN** 2786-6572) є офіційним журналом Всеукраїнської Громадської Спілки "Безперервного професійного розвитку стоматологів"

DOI: 10.56569

Рік заснування: 2021

Періодичність: кожні півроку (березень, жовтень)

Мова видання: англійська, українська

«Український стоматологічний журнал» - міжнародне рецензоване

фахове наукове видання відкритого доступу

УДК: 616.314(477)(05)

UDJ was sent to the publisher on 02.09.2023

Printing format is 60 x 84/8

Offset color printing, coated glossy papers

Volume of 5 physical and 11,2 conventional printed sheets

It's edition of 100 copies circulation

Forms of Journal is produced by LLC PoygraphFactory, Kyiv, Ukraine

Підписане до друку 02.09.2023

Формат 60 x 84/8

Друк кольоровий офсетний. Папір крейдяний глянцевиий

Обсяг 5 фізичних і 11,2 умовних друкованих аркушів

Наклад 100 примірників

Друк ТОВ Поліграфкомбінат, м. Київ, Україна

Diagnostic criteria for odontogenic sinusitis: narrative review of relevant literature data

Roman Popov^{A, C, D, F}

PhD, Associate Professor, Department of Dentistry, O.O. Bogomolets National Medical University, Kyiv, Ukraine
ORCID ID: 0000-0003-3455-5306

Volodymyr Rozumnyi^{B, C, E}

DDS, Private Practice, Kyiv, Ukraine
ORCID ID: 0009-0008-8567-2426

Alisa Sydorenko^{B, C, E}

DDS, Private Practice, Kyiv, Ukraine
ORCID ID: 0009-0009-3302-9233

Liudmyla Kurylekh^{B, C, F}

DDS, Private Practice, Kyiv, Ukraine
ORCID ID: 0009-0008-8695-4265

Olena Logvynenko^{B, C, E}

DDS, Private Practice, Kyiv, Ukraine
ORCID ID: 0009-0002-5499-5122

Corresponding author. Roman Popov, Private Dental Clinic «AVANTO», 37/1, Vasylyia Tyutyunnyka Street, Kyiv, 03680 Ukraine
E-mail address: popov231279@gmail.com

A – research concept and design; B – collection and/or assembly of data; C – data analysis and interpretation; D – writing the article; E – critical revision of the article; F – final approval of article

Article Info

Artical History:

Paper recieved 14 July 2023
Accepted 16 August 2023
Available online 11 December 2023

Keywords:

odontogenic maxillary sinusitis,
diagnosis, literature review

Abstract

Background. Specific tendency could be observed regarding increasing number of odontogenic sinusitis related publications within decades between 1990 and 2019, but even with upgrowing pool of literature data regarding odontogenic sinusitis evidences reported within it remains of low quality. Also, it should be noted that yet no evidence-based consensus decision have been made regarding strict diagnostic criteria of maxillary odontogenic sinusitis.

Objective. To systematize relevant data regarding odontogenic maxillary sinusitis diagnostic criteria based on available guidelines, consensus reports, CBCT-based and clinical researches.

Materials and Methods. Study was provided in the form of retrospective literature review. Search of publications related with the objective of the research was held within PubMed Central database (<https://www.ncbi.nlm.nih.gov/pmc/>) by applying Mesh-terms combinations. Articles included into study group were processed due to the following categories of content-analysis: signs and symptoms which may be used to prove odontogenic origin of maxillary sinusitis; diagnostic significance of different manifestations which may be used to prove odontogenic origin of maxillary sinusitis; approaches which should be followed to provide correct diagnostics of odontogenic maxillary sinusitis.

Results. Out of 15 targeted publications, which formed study group, 2 were represented in the form of systematic review, 1 – in the form of online-survey study, 6 – in the form of literature/comprehensive/state-of-art review, 4 – in the form of retrospective study, 1 – in the form of international multidisciplinary consensus statement, 1 – in the form of experimental imaging study. Considering only one available international multidisciplinary consensus statement regarding odontogenic sinusitis diagnosis next approach should be followed in mentioned order for correct diagnostics of such pathology: 1) suspect odontogenic maxillary sinusitis; 2) confirm sinusitis; 3) confirm odontogenic pathology.

Conclusion. Tomographical methods of examination are more accurate for the odontogenic maxillary sinusitis diagnostics, nevertheless if multidisciplinary diagnostic approach (endoscopy, tomography and clinical examination) is possible for realization it should be held as a primary diagnostic strategy. Cases of asymptomatic maxillary odontogenic sinusitis, while also symptomatic ones developing without background of recent dental treatment, may also be observed in clinical practice, and thus should be correctly diagnosed for appropriate treatment planning.

<https://doi.org/10.56569/UDJ.2.2.2023.114-122>
2786-6572/© 2023 The Author(s).

Published by UDJ on behalf of Ukrainian public scientific society Continuing Dental Education. This is an open access article under the CC BY license (<http://creativecommons.org/licenses/by/4.0/>).

Introduction

Global prevalence of odontogenic sinusitis due to the available systematic review tends to reach 50% per analyzed sinus and 51% per diagnosed patient, thus demonstrating that basically every second maxillary sinusitis potentially is of odontogenic origin [1]. Otolaryngology chief residents reported that up to 40% of unilateral maxillary sinus opacifications may potentially be diagnosed as odontogenic sinusitis signs [2]. It is interesting to note the in 1970s only 10–12% of maxillary sinusitis were categorized as those of odontogenic origin [3].

Prevalence of odontogenic sinusitis during first two years of COVID pandemic increased statistically compared to the period of two years prior to COVID, but clinical manifestations of disease has not differed either in pre-COVID era and during pandemic [4].

Previous meta-analytical data also revealed that most cases of odontogenic sinusitis were caused by iatrogenic factors, while also nearly 45% cases were caused by periodontitis and cysts [5]. Recent data supported previous findings regarding 55.97% of odontogenic sinusitis being caused by iatrogenic factors and increase trend in odontogenic sinusitis epidemiology over the last decade in general [6]. Nowadays endo-perio lesions could be interpreted as one the most common etiological factor observed among patients with maxillary odontogenic sinusitis, but self-reported sinonasal symptoms of patients did not differ significantly among cases with different dental-related etiologies [7].

Specific tendency could be observed regarding increasing number of odontogenic sinusitis related publications within decades between 1990 and 2019, but even with upgrowing pool of literature data regarding odontogenic sinusitis evidences reported within it remains of low quality [8]. Also, it should be noted that, yet no evidence-based consensus decision have been made regarding strict diagnostic criteria of maxillary odontogenic sinusitis. Shukairy et al. highlighted that odontogenic sinusitis was not even mentioned within 2015 Adult Sinusitis Clinical Practice Guidelines and fulfilled less than one page of 2016 Rhinosinusitis International Consensus Statement [2]. Provided survey found out that even otolaryngology chief residents underestimate prevalence of odontogenic sinusitis over CT scans provided for evaluation [2], which may be caused also by the deficiency of established definitive CBCT criterions.

Objective

To systematize relevant data regarding odontogenic maxillary sinusitis diagnostic criteria based on available guidelines, consensus reports, CBCT-based and clinical researches.

Materials and Methods

Literature search protocol

Study was provided in the form of retrospective literature review. Search of publications related with the objective of the research was held within PubMed Central database (<https://www.ncbi.nlm.nih.gov/pmc/>) by applying following Mesh-terms combinations:

- 1st request based on keywords “odontogenic sinusitis” and “diagnostics” – odontogenic[All Fields] AND (“sinusitis”[MeSH Terms] OR “sinusitis”[All Fields]) AND (“Diagnostics (Basel)”[Journal] OR “diagnostics”[All Fields]);
- 2nd request based on keywords “odontogenic sinusitis” and “criteria” – odontogenic[All Fields] AND (“sinusitis”[MeSH Terms] OR “sinusitis”[All Fields]) AND (“standards”[Subheading] OR “standards”[All Fields] OR “criteria”[All Fields]);
- 3rd request based on keywords “odontogenic sinusitis” and “guidelines” – odontogenic[All Fields] AND (“sinusitis”[MeSH Terms] OR “sinusitis”[All Fields]) AND (“guideline”[All Fields] OR “guidelines as topic”[MeSH Terms] OR “guidelines”[All Fields]) [9, 10, 11].

Only publication within 10 year period (2013–2023) and those written in English were included into the primary cohort. Primary literature search was held on 6th of September, and results of

such were used as a main data pool for further literature analysis. Control literature search was provided on the 10th of October to depict the publications published in the period between primary and control literature search. New publications obtained during control literature search was analyzed in the same manner as publications received after primary literature search, while if any new and relevant information was revealed it was added to the already formulated body of the pre-prepared manuscript.

Analysis of collected publications was held in step-by-step manner. At the first step all publications were analyzed based on their title and abstract, and those not relevant to the objective were excluded. Second step included in-depth analysis of remaining articles content considering formulated diagnostic aspects, which were used as eligibility criteria analogues:

- clinical diagnostic criteria of odontogenic sinusitis;
- radiological diagnostic criteria of odontogenic sinusitis;
- complex approaches, guidelines, consensus reports or standards regarding odontogenic sinusitis diagnostics;
- sign and symptoms used to differentiate odontogenic origin of maxillary sinusitis form.

Publications which contained repetitive, non-relevant or non-argumentative information, while also such representing personal opinions, or deficiently formulated statements which were not grounded by the supportive scientific data, or such demonstrated lack of evidences were excluded from the study sample.

Data extraction and content-analysis

Content analysis of publications was held with the use of text mining principles focusing just on the depiction of descriptive diagnostic criteria which may be applied for the verification of odontogenic maxillary sinusitis, so no quantitative analysis was provided over the data extracted from the selected publications. Following categories of content-analysis were formulated:

- signs and symptoms which may be used to prove odontogenic origin of maxillary sinusitis;
- diagnostic significance of different manifestations which may be used to prove odontogenic origin of maxillary sinusitis;
- approaches which should be followed to provided correct diagnostics of odontogenic maxillary sinusitis.

Data categorization and analysis

All the extracted targeted data which was associated with the objective of the research was distributed within cells of Microsoft Excel 2019 spreadsheet software (Microsoft Office, Microsoft, United States) considering adherence to different content-analysis categories. Method of entity-relationship modeling was applied to depict relations among different content-analysis categories and potentially structure them in logical manner representing clinically significant outcomes in the form of scientific manuscript.

Results

Literature search provided through PubMed database revealed following amount of publications for the different combination of Mesh-terms based formulated requests:

- 1st search request – 144 publications;
- 2nd search request – 529 publications;
- 3rd search request – 407 publications.

Exclusion of repetitive articles helped to reduce primary cohort of publications to 274. Analysis provided over titles and abstracts of articles supported further reduction of publications cohort to 89 articles. Out of this number in-depth content analysis revealed that only 15 articles contained information relevant to the formulated categories and objective of the research, which formed final study sample of publication. Out of these 15 publication 2 was represented in the form of systematic review, 1 – in the form of online-survey study, 6 – in the form of literature/comprehensive/state-of-art review, 4 – in the form of retrospective study, 1 – in the form of international multidisciplinary consensus statement, 1 – in the form of experimental imaging study.

Only 1 systematic review dedicated to the maxillary sinusitis

diagnostic criteria was found during literature search. Such systematic review revealed that out of 63 analyzed studies 14 described multidisciplinary approach of pathology verification, 11 articles argue the need to consider time correspondence between dental intervention provided and sinusitis occurrence, 24 papers described the need to precise dental examination, and 53 articles argue the need for CT method use [12].

Considering only one available international multidisciplinary consensus statement regarding odontogenic sinusitis diagnosis

next approach should be followed in mentioned order for correct diagnostics of such pathology:

1. suspect odontogenic maxillary sinusitis;
2. confirm sinusitis;
3. confirm odontogenic pathology [13].

Provided literature analysis revealed following dental, sinonasal and CBCT manifestations of odontogenic maxillary sinusitis mentioned in Table 1.

Table 1. Clinical, sinonasal and CBCT manifestations of odontogenic maxillary sinusitis

Clinical dental manifestations	Sinonasal manifestations	CBCT signs
Tooth pain (rare)	Unilateral pattern of symptoms	Unilateral pattern of symptoms
Tooth sensitivity	Purulent meatal rhinorrhea	Mucous thickening of more than 2 mm related with dental originated factor (foreign body, roots, periapical pathology) / Radio-opaque zone over the tooth apex
Mostly related in the region of maxillary molars	Nasal obstruction	Oroantral fistula
Anamnesis of dental interventions or dental pathology	Sensitivity in the projection of the anterior part of the maxilla	Periapical abscess on the background of present periodontal disease / Radiotransparency at the periradicular zone of tooth with diagnosed pulpal pathology
	Postnasal drip	Patent ethmoid infundibulum (sphenoid sinus)
	Malodor secretions	Interruption of lamina dura at the projection of sinus floor over the area of tooth-related radiolucency
	Pronounced swelling and congestion of maxillary sinus	Radiopacity of sinus space of various degree (high values of textural homogeneity)

Discussion

During the suspicion of odontogenic sinusitis, which usually is presented by unilateral pattern of symptoms and radiopacity, foul smell, adjacent dental pathology, purulent meatal rhinorrhea, Craig J. highlighted two principal diagnostic tenets: confirmation of sinusitis pathology itself (by the endoscopy) and confirmation of potential dental source of such [13, 14].

Signs and symptoms of odontogenic sinusitis may be categorized into those being related with dental and sinonasal manifestations [15].

Dental signs includes tooth pain or sensitivity, which in the first place may not directly point on the sinus problems, but such are worsening with the sinusitis progression [15]. On the other hand Little et al. highlighted that dental pain usually absent during odontogenic sinusitis, and if such is present without other sinusitis symptoms, that indirectly means that final diagnosis would not be the odontogenic sinusitis [16]. Due to the various literature data the maxillary molar region remains the most frequently involved during odontogenic sinusitis with first molar associated with over 20% of all cases, and second and third molar – with nearly 15-20% cases each [3].

From dental specialists' perspective following assertions reached agreement regarding diagnostics of odontogenic maxillary sinusitis within only available international multidisciplinary consensus statement:

1. dental caries without pulpal involvement should not cause sinusitis;
2. CBCT is the more accurate method to diagnose odontogenic sinusitis compared to periapical radiography, while bite-wing being not acceptable at all for this purpose;
3. vital inflamed pulp (pulpitis) may cause mucous membrane thickening without any sinus opacification;
4. in the conditions of early apical periodontitis or if apical periodontitis develops in the condition of absent periapical cortical bone plate, odontogenic sinusitis may take place without any adjacent radiographic bone changes [13].

Sinonasal manifestations include nasal obstruction, rhinorrhea,

sensitivity in the projection of the anterior part of the maxilla, postnasal drip, which are typical also for non-odontogenic sinus pathologies, but anamnesis of dental interventions or dental diseases help to distinguish odontogenic origin [15]. Nevertheless it should be taken into account that less than half of patients with odontogenic sinusitis report recent dental interventions [16]. Newsone H.A. et al. pointed that malodor secretions is of high diagnostic significance for odontogenic sinusitis diagnostics [17]. Also it was found that patients with maxillary sinusitis of odontogenic origin characterized with greater swelling and congestions compare to patients with non-odontogenic origin of disease [17]. Analogical results were obtained in Fredriksson M.V. study revealing that patients with odontogenic sinusitis has more pronounced swelling and congestion of maxillary sinus, while also the frequency of cases for 2/3 of maxillary volume being congested among odontogenic sinusitis was nearly twofold higher than in non-odontogenic [18]. Maxillary fluid excretion and mucous thickening also demonstrated greater values among odontogenic sinusitis patients compared to patients with non-odontogenic sinusitis pathology [17]. Most of odontogenic maxillary sinusitis cases are unilateral, so bilateral pattern of changes lowers the chance of odontogenic origin disease diagnosis [12].

Previous data reported that 55-86% of dental pathologies associated with odontogenic maxillary sinusitis may be missed on conventional dental radiographs [3]. Sensitivity and specificity of CT for odontogenic maxillary sinusitis identification were 89.7% and 94.6% correspondingly; such parameters of orthopantomography reached 68.2% and 77.3%, while of periapical radiography – 77.9% and 67% respectively [19]. Nevertheless, previous data has revealed that 60-70% cases of odontogenic sinusitis have been missed by dental radiologists during CT scans analysis [14]. Current concepts of odontogenic sinusitis diagnostics based on imaging approach include following triad of criteria: 1) oroantral fistula; 2) periapical abscess on the background of present periodontal disease; 3) presence of molar or premolar with prominent periodontal disease signs [17] (Figure 1-3).

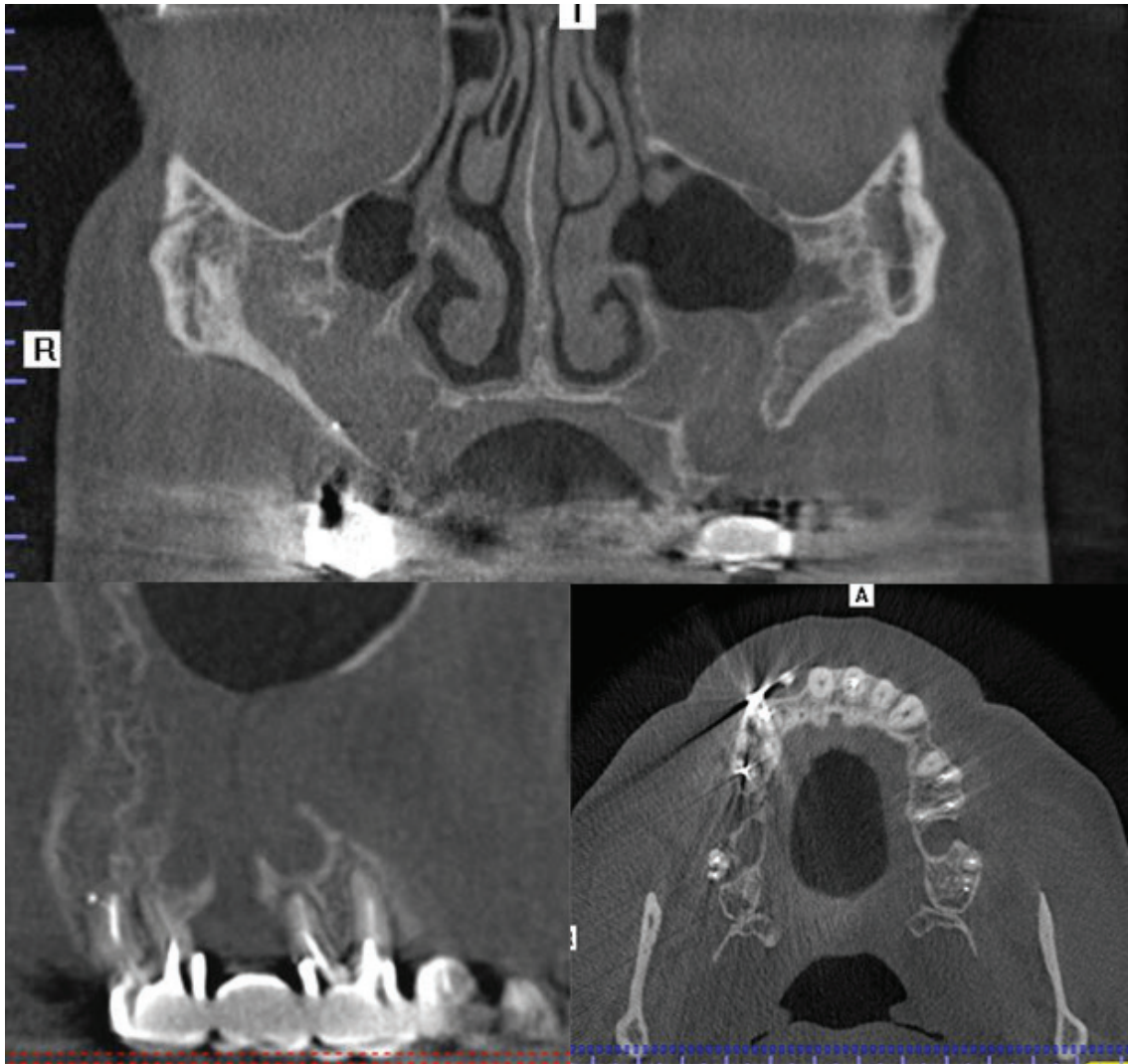

Figure 1. Bilateral odontogenic maxillary sinusitis, left side oroantral fistula

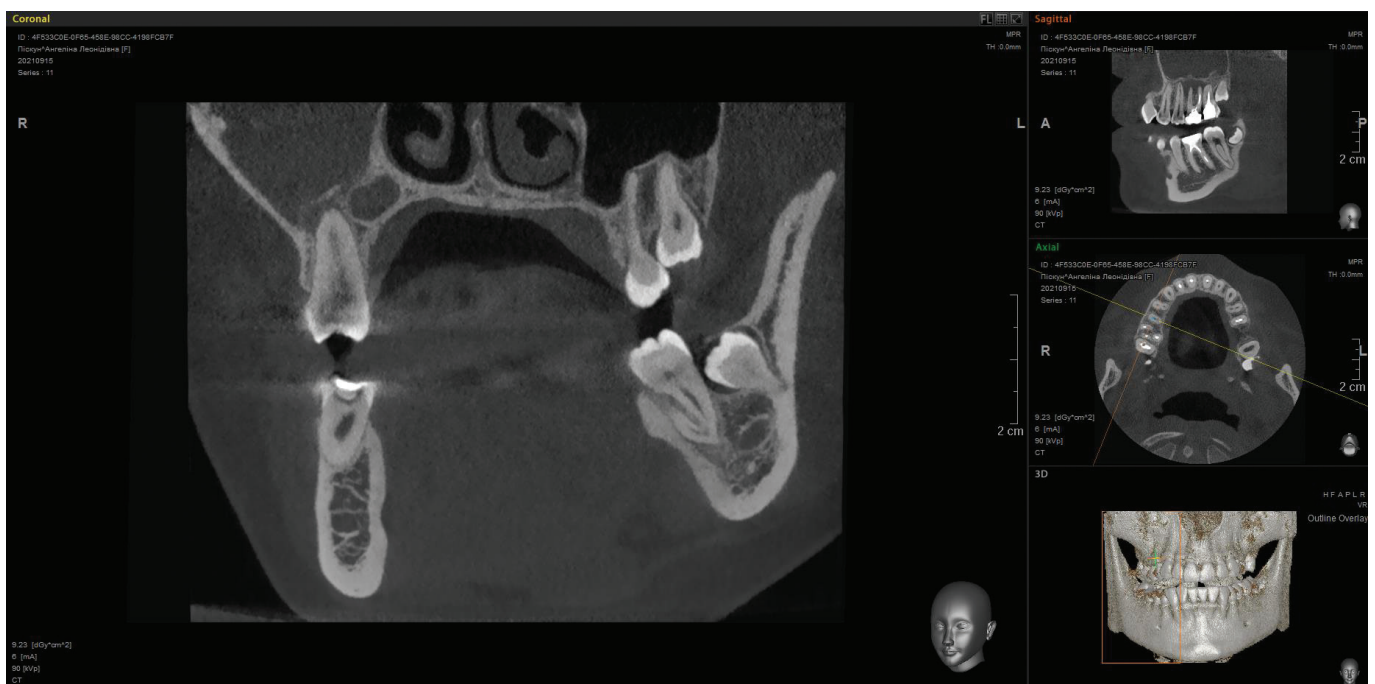


Figure 2. Odontogenic maxillary sinusitis originated from tooth 1.5

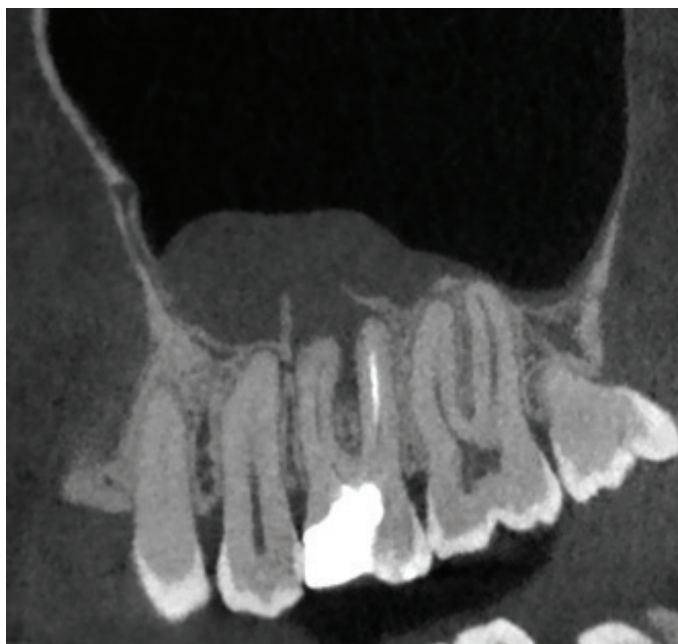


Figure 3. Odontogenic maxillary sinusitis originated from tooth 1.6

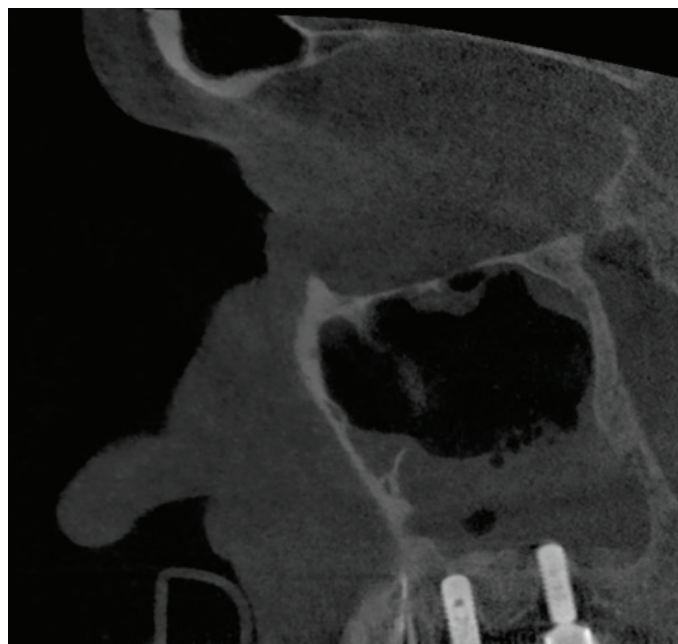

Figure 4. Odontogenic maxillary sinusitis originated from peri-implantitis pathology

CT scans represent odontogenic sinusitis on the axial and coronal planes with the mucous thickening of more than 2 mm related with dental originated factor (foreign body, roots, implants, periapical pathology) (Figure 4).

It has been found that near two thirds of patients with odontogenic sinusitis characterized with present periradicular infections signs, while one third have no such CT-manifestations. Such outcome may be caused by the absent cortical plate between problematic tooth and affected sinus [3] (Figure 5).

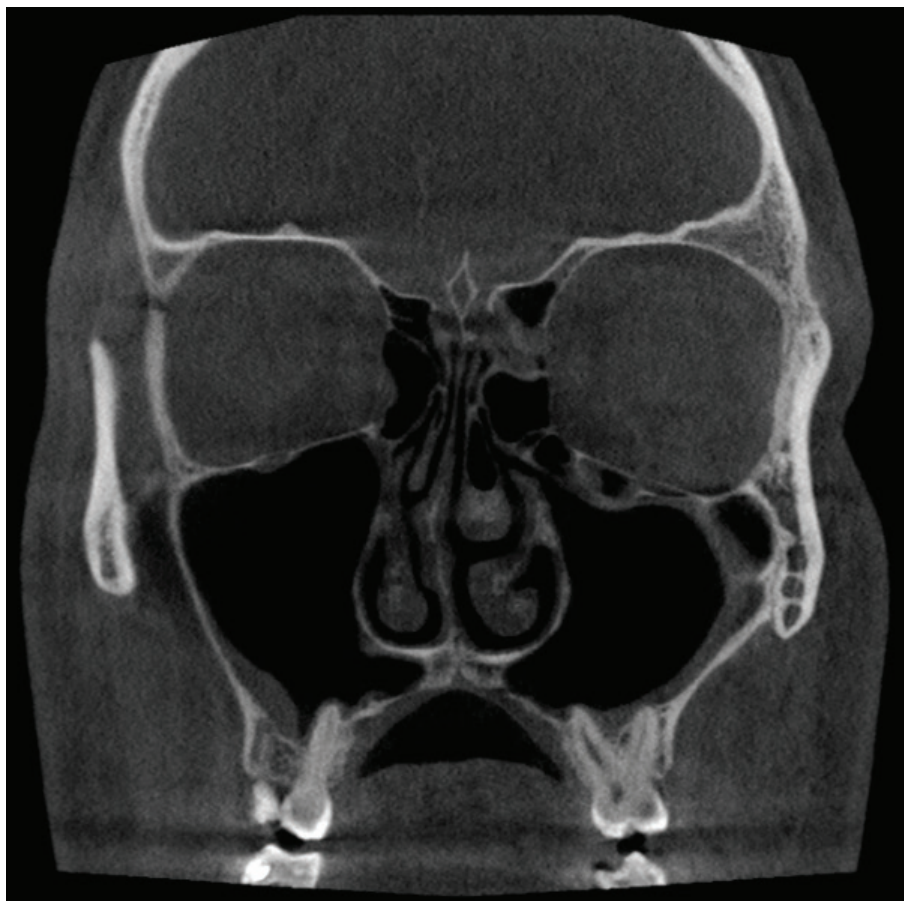


Figure 5. Absent cortical plate in the projection of tooth 1.6

On the CBCT scans patients with odontogenic sinusitis represent higher values of textural homogeneity, while non-odontogenic sinusitis patients demonstrated greater levels of contrast [20].

Goyal et al. proposed to use another four criteria for odontogenic sinusitis prediction: ipsilateral facial pressure, suppuration from middle meatus during endoscopic diagnostics, frontal sinus opacification on the CT-scans, while also the presence of foul smell [21]. The most powerful regressor among all above-mentioned was the presence of pus at the middle meatus during endoscopy, which stands for odds ratio of odontogenic sinusitis equal to 17.67. On the other hand authors also pointed that opacification within sphenoid sinus is inversely related with possibility of odontogenic sinusitis diagnosis (odds ratio – 0.14) [21]. Analogical interrelation was also

described in the Newsome H.A. paper: maxillary odontogenic sinusitis patients in 75% of cases represent patent ethmoid infundibulum, so such CT findings may be used as indirect suggestion for odontogenic origin of the pathology [17].

So called endo-antral syndrome includes following complex of changes: endodontic pathology with sinus involvement, radiotransparency at the periradicular zone of tooth with diagnosed pulpal pathology, interruption of lamina dura at the projection of sinus floor over the area of tooth-related radiolucency, sinus membrane thickening, and hypertrophy represented by radio-opaque zone over the tooth apex, radiopacity of sinus space of various degree [22] (Figure 6).

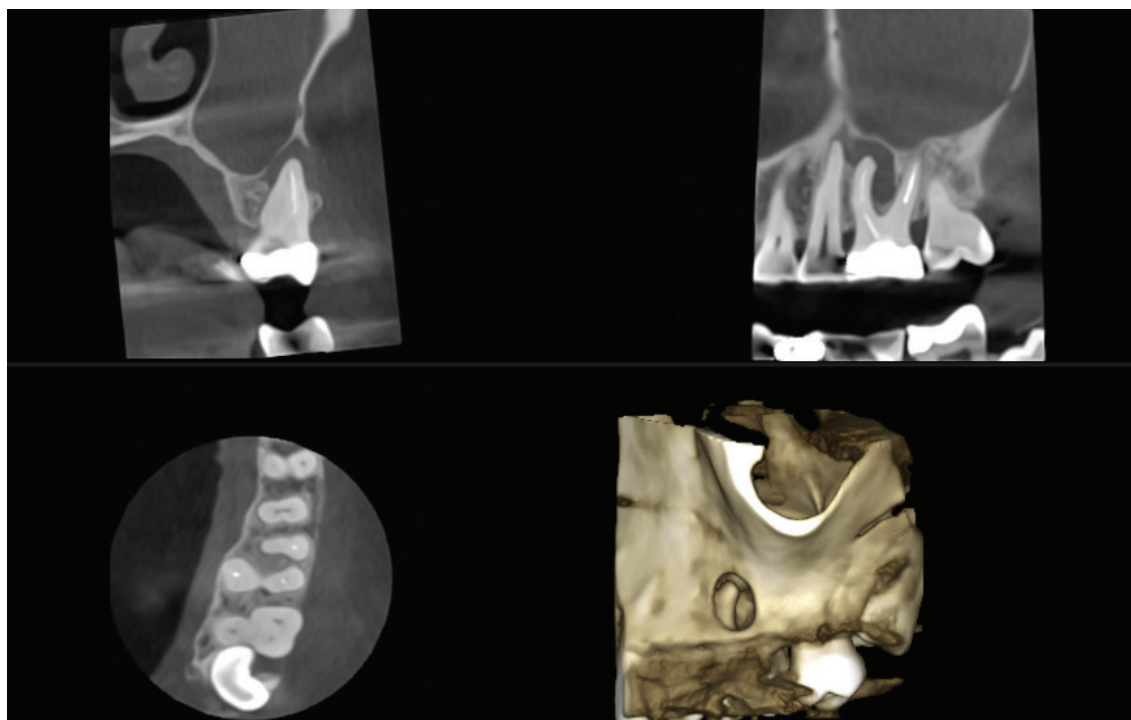


Figure 6. Odontogenic maxillary sinusitis originated from tooth 1.6

It also has been found that endoscopic signs of odontogenic maxillary sinusitis correlates with subjective symptomatology in greater manner compared to endodontic signs [22].

Avrunin and colleagues proposed specific algorithm for automated diagnosis of odontogenic sinusitis based on densitometric analysis held over frontal multiplanar reconstruction, while also discriminant model based on the relative indicator of the opening area of the anastomosis, relative index of the volume of the sinus mucosa, relative indicator of the volume of fluid content of the sinus, aerodynamic nose drag coefficient for differentiation acute serous and acute purulent forms of sinusitis, and also its acute and chronic forms [23].

Craig J. highlighted specific clinical scenarios which may take place during diagnostics of patients with possible odontogenic sinusitis, while also providing further suggestions for interventions [13, 14]:

- confirmed sinusitis with such suspected to be of dental origin, but no dental pathology present at CT scan is possible scenario, because near 30% of patients demonstrated no periapical lesions while having maxillary odontogenic sinusitis;
- confirmed sinusitis with such suspected to be of dental origin, but dental examination did not revealed prominent dental etiology – in this case dental intervention may be categorized as being option of treatment, while also option of diagnostics;
- confirmed dental etiology and suspected sinusitis, but endoscopy results are inconclusive – other diagnostic signs should be taken into account to provide definitive diagnostics;

- confirmed dental etiology, but only mucosal thickening of sinus present on the CT scan – dental pathology should be treated, and monitoring should be organized, since absence of purulent exudation from middle meatus is a sign that exclude odontogenic maxillary sinusitis diagnosis;

- asymptomatic maxillary odontogenic sinusitis may be observed among 15% of patients, and for such cases at least dental treatment should be initiated [13, 14].

International multidisciplinary consensus statement regarding diagnosis of odontogenic sinusitis included following assertions which reached agreement among dental specialists and otolaryngologists:

- 1) multidisciplinary diagnostics approach is beneficial for maxillary odontogenic sinusitis diagnostics;
- 2) if odontogenic origin of sinusitis may be suspected patient should be referred to dental specialist;
- 3) if dental patient demonstrates any CT signs of sinus pathology with or without adjacent sinus pathology symptomatics, he or she may be referred to otolaryngologists;
- 4) if maxillary odontogenic sinusitis may be suspected after dental implant placement, patient should be referred to dental specialist to verify further functional prognosis of titanium screw;
- 5) following symptoms should be screened for odontogenic maxillary sinusitis: foul smell, loss of smell, posterior nasal drainage, anterior nasal drainage, nasal obstruction, and facial pressure;
- 6) during suspicion of dental origin of maxillary sinusitis patients

should be screened on dental pain and prior dental pathologies or interventions;

7) if maxillary odontogenic sinusitis is highly suspected but dental examination did not revealed any related dental pathology, odontogenic nature of sinusitis should still be considered for ongoing sinus oedema cases or purulent discharge after proper endoscopic surgery and antibiotic therapy [13].

Conclusion

Confirmation of odontogenic maxillary sinusitis diagnosis remains a challenge for the dental clinicians, nevertheless step-by-step approach should be provided for the cases with such pathology suspicion, which in the first place includes confirmation of sinusitis pathology itself, and then – its odontogenic origin. Tomographical methods of examination are more accurate for the odontogenic maxillary sinusitis diagnostics, nevertheless if multidisciplinary diagnostic approach (endoscopy, tomography and clinical examination) is possible for realization it should be held as a primary diagnostic strategy. Cases of asymptomatic maxillary odontogenic sinusitis, while also symptomatic ones developing without background of recent dental treatment, may also be observed in clinical practice, and thus should be correctly diagnosed for appropriate treatment planning.

Conflict of Interest

Authors do not have any potential conflict of interests that may influence the decision to publish this article.

Funding

No funding was received to assist in preparation and conduction of this research, as well as in composition of this article.

References

- Vitali FC, Santos PS, Massignan C, Maia LC, Cardoso M, da Silveira Teixeira C. Global prevalence of maxillary sinusitis of odontogenic origin and associated factors: a systematic review and meta-analysis. *J Endod.* 2023;49(4):369-81. doi: 10.1016/j.joen.2023.01.010
- Shukairy MK, Burmeister C, Ko AB, Craig JR. Recognizing odontogenic sinusitis: A national survey of otolaryngology chief residents. *Am J Otolaryngol.* 2020;41(6):102635. doi: 10.1016/j.amjoto.2020.102635
- Psillas G, Papaioannou D, Petsali S, Dimas GG, Constantinidis J. Odontogenic maxillary sinusitis: A comprehensive review. *J Dent Sci.* 2021;16(1):474-81. doi: 10.1016/j.jds.2020.08.001
- Ringel B, Kons ZA, Holbrook EH, Gray ST. Trends of Odontogenic Sinusitis Incidence During the COVID-19 Pandemic. *The Laryngoscope.* 2023;online ahead of print. doi: 10.1002/lary.31082
- Irimia ÓA, Dorado CB, Marino JS, Rodríguez NM, González JM. Meta-analysis of the etiology of odontogenic maxillary sinusitis. *Med Oral Patol Oral Cir Bucal.* 2010;15(1):e70-3. doi: 10.4317/medoral.15.e70
- Nurchis MC, Pascucci D, Lopez MA, Moffa A, Passarelli PC, Bressi F, Casale M, Damiani G. Epidemiology of odontogenic sinusitis: an old, underestimated disease, even today. A narrative literature review. *J Biol Regul Homeost Agents.* 2020;34(5 Suppl. 3):195-200.
- Wu J, Zheng M, Wang X, Wang S. Endo-Periodontal Lesions—An Overlooked Etiology of Odontogenic Sinusitis. *J Clin Med.* 2023;12(21):6888. doi: 10.3390/jcm12216888
- Shin JM, Kim SJ, Lee HM, Park IH. Changing Trends in the Clinical Characteristics and Treatment Strategies for Odontogenic Sinusitis Over the Past 10 Years. *Ear, Nose Throat J.* 2022;01455613221080918. doi: 10.1177/01455613221080918
- Fatehi F, Gray LC, Wootton R. How to improve your PubMed/MEDLINE searches: 3. advanced searching. *MeSH and My NCBI. J Telemed Telecare.* 2014;20(2):102-12. doi: 10.1177/1357633X13519036
- Kim S, Yeganova L, Wilbur WJ. Meshable: searching PubMed abstracts by utilizing MeSH and MeSH-derived topical terms. *Bioinformatics.* 2016;32(19):3044-6. doi: 10.1093/bioinformatics/btw331
- Mao Y, Lu Z. MeSH Now: automatic MeSH indexing at PubMed scale via learning to rank. *J Biomed Semantics.* 2017;8(1):15. doi: 10.1186/s13326-017-0123-3
- Allevi F, Fadda GL, Rosso C, Martino F, Pipolo C, Cavallo G, Felisati G, Saibene AM. Diagnostic criteria for odontogenic sinusitis: a systematic review. *Am J Rhinol Allergy.* 2021;35(5):713-21. doi: 10.1177/1945892420976766
- Craig JR, Poetker DM, Aksoy U, Allevi F, Biglioli F, Cha BY, Chiapasco M, Lechien JR, Safadi A, Simuntis R, Tataryn R. Diagnosing odontogenic sinusitis: An international multidisciplinary consensus statement. *Int Forum Allergy Rhinol.* 2021;11(8):1235-1248. doi: 10.1002/alr.22777
- Craig JR. Odontogenic sinusitis: A state-of-the-art review. *Word J Otorhinolaryngol Head Neck Surg.* 2022;8(01):8-15. doi: 10.1002/wjo2.9
- Kim SM. Definition and management of odontogenic maxillary sinusitis. *Maxillofac Plast Reconstr Surg.* 2019;41(1):13. doi: 10.1186/s40902-019-0196-2
- Little RE, Long CM, Loehrl TA, Poetker DM. Odontogenic sinusitis: A review of the current literature. *Laryngoscope Investig Otolaryngol.* 2018;3(2):110-4. doi: 10.1002/lio2.147
- Newsome HA, Poetker DM. Odontogenic sinusitis: Current concepts in diagnosis and treatment. *Immunol Allergy Clin North Am.* 2020;40(2):361-9. doi: 10.1016/j.jiac.2019.12.012
- Vestin Fredriksson M, Kuoljok J, Flygare L, Berggren D, Tano K. Clinical manifestations and symptoms of maxillary sinusitis of odontogenic origin demonstrated by cone beam computed tomography. *J Gen Pract.* 2019;7(1):371 doi: 10.4172/2329-9126.1000374
- Simuntis R, Kubilius R, Padervinskis E, Ryškieienė S, Tušas P, Vaitkus S. Clinical efficacy of main radiological diagnostic methods for odontogenic maxillary sinusitis. *Eur Arch Otorhinolaryngol.* 2017;274:3651-8. doi: 10.1007/s00405-017-4678-5
- Costa AL, Fardim KA, Ribeiro IT, Jardim MA, Braz-Silva PH, Orhan K, de Castro Lopes SL. Cone-beam computed tomography texture analysis can help differentiate odontogenic and non-odontogenic maxillary sinusitis. *Imaging Sc Dent.* 2023;53(1):43-51. doi: 10.5624/isd.20220166
- Goyal VK, Spillinger A, Peterson EI, Craig JR. Odontogenic sinusitis publication trends from 1990 to 2019: a systematic review. *Eur Arch Otorhinolaryngol.* 2021 278(10):3857-3865. doi: 10.1007/s00405-021-06688-7.
- Martu C, Martu MA, Maftai GA, Diaconu-Popa DA, Radulescu L. Odontogenic Sinusitis: From Diagnosis to Treatment Possibilities—A Narrative Review of Recent Data. *Diagnostics.* 2022;12(7):1600. doi: 10.3390/diagnostics12071600
- Avrunin OG, Nosova YV, Abdelhamid IY, Pavlov SV, Shushliapina NO, Wójcik W, Kisała P, Kalizhanova A. Possibilities of automated diagnostics of odontogenic sinusitis according to the computer tomography data. *Sensors.* 2021;21(4):1198. doi: 10.3390/s21041198

Діагностичні критерії одонтогенного синуситу: нарративний огляд релевантних літературних даних

Роман Попов ^{A, C, D, F}

PhD, доцент, Національний Медичний Університет ім. О.О. Богомольця, Київ, Україна
ORCID ID: 0000-0003-3455-5306

Володимир Розумний ^{B, C, E}

лікар-стоматолог, приватна практика, Київ, Україна
ORCID ID: 0009-0008-8567-2426

Аліса Сідоренко ^{B, C, E}

лікар-стоматолог, приватна практика, Київ, Україна
ORCID ID: 0009-0009-3302-9233

Людмила Курилех ^{B, C, F}

лікар-стоматолог, приватна практика, Київ, Україна
ORCID ID: 0009-0008-8695-4265

Олена Логвиненко ^{B, C, E}

лікар-стоматолог, приватна практика, Київ, Україна
ORCID ID: 0009-0002-5499-5122

Відповідальний автор для листування: Роман Попов, Приватна стоматологічна клініка «AVANTO», вул. Василя Тютюнника, 37/1, Київ, 03680 Україна
E-mail address: popov231279@gmail.com

A – розробка концепції та дизайну дослідження, B – збір та або систематизація даних дослідження, C – аналіз та тлумачення даних дослідження, D – написання публікації, E – критичне доопрацювання тексту публікації, F – остаточне затвердження.

Стаття:

Історія статті:

Надійшла до редакції 14 липня 2022
Прийнята до друку 16 серпня 2023
Доступна онлайн 11 грудня 2023

Ключові слова:

одонтогенний верхньощелеповий синусит, діагностика, огляд літератури

Анотація

Вступ. Відмічається специфічна тенденція щодо зростання кількості публікацій, присвячених тематиці одонтогенного синуситу, у період десятиліть між 1990 та 2019 роками, проте навіть при збільшенні пулу літературних даних, асоційованих із тематикою одонтогенного синуситу, доступні докази в структурі такого характеризуються низькою якістю. Також слід зазначити, що досі не було прийнято консенсусного рішення на основі доступних доказів щодо строго-визначених критеріїв діагностики верхньощелепового одонтогенного синуситу.

Мета. Систематизувати відповідні дані щодо діагностичних критеріїв одонтогенного верхньощелепового синуситу на основі наявних рекомендацій, консенсусних звітів, КПКТ- та клінічних досліджень.

Матеріали та методи. Дослідження проводилось у формі ретроспективного огляду літератури. Пошук публікацій, пов'язаних з метою дослідження, проводився у базі даних PubMed Central (<https://www.ncbi.nlm.nih.gov/pmc/>) із застосуванням комбінацій Mesh-термінів. Статті, котрі були включені до досліджуваної групи, були опрацьовані з врахуванням наступних категорій контент-аналізу: ознаки та симптоми, за якими можна довести одонтогенне походження верхньощелепового синуситу; діагностичне значення різних проявів, за допомогою яких можна довести одонтогенне походження гаймориту; підходи, яких необхідно дотримуватися для правильної діагностики одонтогенного верхньощелепового синуситу.

Результати. Із 15 цільових публікацій, включених до групи дослідження, 2 були представлені у формі систематичних оглядів, 1 – у формі онлайн-опитування, 6 – у формі літературного/ комплексного/аналітичного оглядів, 4 – у формі ретроспективного дослідження, 1 – у формі міжнародної міждисциплінарної консенсусної заяви, 1 – у формі експериментального візуалізаційного дослідження. Враховуючи наявність лише одного доступного міжнародного міждисциплінарного консенсусного рішення щодо діагностики одонтогенного синуситу, для правильної діагностики даної патології слід дотримуватися наступного підходу у зазначеному порядку: 1) констатувати підозру на одонтогенний верхньощелеповий; 2) підтвердити діагноз синуситу; 3) підтвердити його одонтогенну етіологію.

Висновки. Томографічні методи дослідження є одними з найбільш точних для діагностики одонтогенного верхньощелепового синуситу, проте при можливості реалізації мультидисциплінарного діагностичного підходу (ендоскопія, томографія та клінічне обстеження), такий слід розглядати у якості першочергової стратегії діагностики. У клінічній практиці також можуть спостерігатися випадки безсимптомного протікання верхньощелепового одонтогенного

синуситу, а також одонтогенного синуситу, який може розвиватися без підтверджених фактів нещодавнього стоматологічного лікування в анамнезі, відтак такі випадки також потребують коректної діагностики для послідуєчого належного планування лікування.

Конфлікт інтересів

Автори не мають потенційного конфлікту інтересів, який може вплинути на рішення про публікацію цієї статті.

<https://doi.org/10.56569/>

UDJ.2.2.2023.114-122

2786-6572/© 2023 The Author(s).

Заява про фінансування

Автори не отримували фінансової підтримки від жодної організації для проведення свого дослідження
