

Journal of

CONTINUING DENTAL
EDUCATION

UKRAINIAN PUBLIC SCIENTIFIC SOCIETY

Volume 2 • Issue 2 • October 2023

U D J

Ukrainian Dental Journal

У К Р А Ї Н С Ь К И Й
С Т О М А Т О Л О Г І Ч Н И Й
Ж У Р Н А Л

Editor-in-Chief

Larysa Dakhno
Institute of Dentistry, Shupyk National Medical Academy of
Postgraduate Education, Kyiv, Ukraine
Central Laboratory diagnosis of the head, Kyiv, Ukraine

Associate Editors

Myroslav Goncharuk-Khomyn
Uzhhorod National University, Uzhhorod, Ukraine

Editorial board.

Nataliia Bidenko, Kyiv, Ukraine
Michele Callea, Florence, Italy
Lyubov Smaglyuk, Poltava, Ukraine
Kostiantyn Lykhota, Kyiv, Ukraine
Hanna Vyshnevskya, Odesa, Ukraine
Özkan Adıgüzel, Diyarbakır, Turkey
Roberto Fornara, Milano, Italy
Yasemin Yavuz, Sanliurfa, Turkey
Antonino Morabito, Florence, Italy
Iryna Logvynenko, Kyiv, Ukraine
Yaroslav Shkorbotun, Kyiv, Ukraine

Art Designer

Yaroslava Biruk, Kyiv, Ukraine

Founder and Publisher

Ukrainian Public Scientific Society "Continuing Dental Education"
Address: 15, Kyrylivska str., Kyiv, 04080, Ukraine
E-mail: editor.udj@gmail.com
Website: www.journal.dental.ua

Certificate of State Registration of Print Media

Series KB № 25041 - 14981P from 30.11.2021

Certificate of making a publishing house subject to the State Register of publishers, manufacturers and distributors of publishing products

Series ДК №7617 from 01.06.2022
Ukrainian Dental Journal (p-ISSN 2786-6297; e-ISSN 2786-6572)
is official Journal of the Ukrainian Public Scientific Society for
Continuing Dental Education

DOI: 10.56569

Published: from the year 2021

Frequency: semiannual (March, October)

Manuscript Languages: English, Ukrainian

Ukrainian Dental Journal accepts articles for Open Access publication

UDC: 616.314(477)(05)

Головний редактор

Лариса Дахно
Інститут стоматології Національного університету охорони
здоров'я України імені П. Л. Шупика, Київ, Україна
Central Laboratory diagnosis of the head, Київ, Україна

Заступник головного редактора

Мирослав Гончарук-Хомин
Ужгородський національний університет, Ужгород, Україна

Редколегія

Наталія Біденко, Київ, Україна
Мікеле Каллеа, Флоренція, Італія
Любов Смаглюк, Полтава, Україна
Костянтин Лихота, Київ, Україна
Ганна Вишневська, Одеса, Україна
Озкан Адігузель, Діярбакир, Туреччина
Роберто Форнара, Мілан, Італія
Ясемін Явуз, Шанлиурфа, Туреччина
Антоніно Морабіто, Флоренція, Італія
Ірина Логвиненко, Київ, Україна
Ярослав Шкорботун, Київ, Україна

Дизайн та верстка

Ярослава Бірюк, Київ, Україна

Засновник і Видавець

ГС "Безперервного професійного розвитку стоматологів"
Адреса: 04080, Україна, м. Київ, вул. Кирилівська, 15
Електронна адреса: editor.udj@gmail.com
Веб-сайт: www.journal.dental.ua

Свідоцтво про державну реєстрацію друкованого ЗМІ

Серія KB № 25041 - 14981P від 30.11.2021

Свідоцтво про внесення суб'єкта видавничої справи до Державного реєстру видавців, виготовлювачів і розповсюджувачів видавничої продукції

Серія ДК №7617 від 01.06.2022
Український стоматологічний журнал (p-ISSN 2786-6297; e-ISSN 2786-6572) є офіційним журналом Всеукраїнської Громадської Спілки "Безперервного професійного розвитку стоматологів"

DOI: 10.56569

Рік заснування: 2021

Періодичність: кожні півроку (березень, жовтень)

Мова видання: англійська, українська

«Український стоматологічний журнал» - міжнародне рецензоване фахове наукове видання відкритого доступу

УДК: 616.314(477)(05)

UDJ was sent to the publisher on 02.09.2023

Printing format is 60 x 84/8

Offset color printing, coated glossy papers

Volume of 5 physical and 11,2 conventional printed sheets

It's edition of 100 copies circulation

Forms of Journal is produced by LLC PoygraphFactory, Kyiv, Ukraine

Підписане до друку 02.09.2023

Формат 60 x 84/8

Друк кольоровий офсетний. Папір крейдяний глянцевиий

Обсяг 5 фізичних і 11,2 умовних друкованих аркушів

Наклад 100 примірників

Друк ТОВ Поліграфкомбінат, м. Київ, Україна

Regenerative endodontics: vary of scaffolds and its benefits for pediatric dentistry

Oleg Kovnatskyi ^{A, B, C, D}
DMD, Private practice, Kyiv, Ukraine
ORCID ID: 0009-0000-8188-4319

Stanislav Geranin ^{E, F}
PhD, Department of Dentistry, V. N. Karazin Kharkiv National, Kharkiv, University Ukraine
ORCID ID: 0000-0002-4266-9189

Corresponding author. Oleg Kovnatskyi: Alishera Navoi ave 69, 258, 02130 Kyiv, Ukraine
E-mail: kovnatskyioleg@gmail.com

A - research concept and design; B - collection and/or assembly of data; C - data analysis and interpretation; D - writing the article; E - critical revision of the article; F - final approval of article

Article Info

Artical History:
Paper recieved 06 August 2023
Accepted 22 August 2023
Available online 11 December 2023

Keywords:
pulp scaffold, regenerative endodontics,
dental pulp regeneration,
pulp revascularization, immature
permanent teeth, pediatric dentistry,
literature review

<https://doi.org/10.56569/UDJ.2.2.2023.107-113>
2786-6572/© 2023 The Author(s). Published
by UDJ on behalf of Ukrainian public scientific
society Continuing Dental Education. This is
an open access article under the CC BY license
(<http://creativecommons.org/licenses/by/4.0/>).

Abstract

Background. Regenerative Endodontic Procedures deliver a suitable environment to promote natural regeneration/repair with a functional pulp–dentin wall and apical closure. However, REPs have a number of features that can complicate their implementation, especially for children. One of them is scaffold formation.

Objective. To describe alternative scaffold formation options for pulp revitalization and compare their effectiveness and describe possible causes of periapical tissues not bleeding during endodontic regenerative procedures.

Materials and methods. A comprehensive search strategy was done through PubMed and Cochrane Library databases by using MESH terms equivalent to the keywords. Review articles for the last 5 years were selected according to the keywords with exclusion criteria.

Results. According to the search criteria and keywords, 801 articles were obtained, after applying the exclusion criteria, 11 ones that met the selection requirements were left.

Conclusions. The main method of scaffold obtaining is the blood clot formation. However, if it is not possible to make the periapical tissues bleed for clot formation, then the use of platelet-enriched autologous plasma or platelet-rich fibrin is recommended. This technique has proven to be as effective as the main one. It can prevent painfulness caused by bleeding provoking for blood clot formation.

Introduction

Treatment of immature permanent teeth with necrotic pulp characterized with various challenges and unpredicted prognosis, if such is provided not following the strict clinical algorithm [1].

For a long time the treatment of choice for immature permanent teeth with necrotic pulp used to be apexification with calcium hydroxide. Later it was widely replaced by apical barrier formation with MTA followed by root canal obturation.

Previous systematic reviews concluded that the long term use of calcium hydroxide in the root canals of immature teeth should be avoided, so apexification with calcium hydroxide is no longer advocated [2]. The evidence supporting the use of Regenerative Endodontic Procedures was extremely weak and therefore this technique was used in rare cases where prognosis regarding other techniques is deemed to be extremely poor [2].

But new systematic reviews show that revascularization (as a part of Regenerative Endodontic Procedures) provides clinical success similar to apexification with MTA-apical plug [3].

Oftentimes immature permanent teeth with necrotic pulp is the case for kids and adolescents who had negative dental experience. This kind of experience can make the endodontic management of immature permanent teeth with necrotic pulp troublesome.

The solution requires modified behavioral management and low complexity procedures with minimal time duration as a preference. Because of this endodontic management of immature permanent teeth becomes much more challenging.

Revascularization or revitalization is the technique of regenerative endodontics that has a unique potential advantage [4]. Regenerative Endodontic Procedures (REPs) are described as “biologically based procedures designed to replace damaged structure” and aim to deliver a suitable environment to promote natural regeneration/repair with a functional pulp–dentin wall and apical closure [5, 6]. Therefore, REPs have the potential to increase root length, to thicken the root wall, and to achieve apical closure [7–9].

According to moderate complexity of revascularization clinical procedures and clinical effects that cannot be achieved by other means (increased root wall thickness and/or increased root length, positive response to vitality testing [10]) this technique is promising for young patients with negative dental experience.

REPs were first established by Nygaard-Ostby in the 1960s, though with low success [11–13]. As of today REPs are one of the most challenging and cutting-edge topics in regenerative dentistry. The American Association for Endodontists (AAE) [10] have recently delivered position statements and clinical considerations regarding REPs (Table 1).

Table 1. AAE Clinical Considerations for a Regenerative Procedure [10]

Case Selection:	<p>Tooth with necrotic pulp and an immature apex. Pulp space not needed for post/core, final restoration. Compliant patient/parent. Patients not allergic to medicaments and antibiotics necessary to complete procedure (ASA* 1 or 2).</p>
Informed Consent	<p>Two (or more) appointments. Use of antimicrobial(s). Possible adverse effects: staining of crown/root, lack of response to treatment, pain/infection. Alternatives: MTA** apexification, no treatment, extraction (when deemed nonsalvageable). Permission to enter information into AAE*** database (optional).</p>
First Appointment	<p>Local anesthesia, dental dam isolation and access. Copious, gentle irrigation with 20ml NaOCl using an irrigation system that minimizes the possibility of extrusion of irrigants into the periapical space (e.g., needle with closed end and side-vents, or EndoVac™). Lower concentrations of NaOCl are advised [1.5% NaOCl (20mL/canal, 5 min) and then irrigated with saline or EDTA**** (20 mL/canal, 5 min), with irrigating needle positioned about 1 mm from root end, to minimize cytotoxicity to stem cells in the apical tissues. Dry canals with paper points. Place calcium hydroxide or low concentration of triple antibiotic paste. If the triple antibiotic paste is used: 1) consider sealing pulp chamber with a dentin bonding agent [to minimize risk of staining] and 2) mix 1:1:1 ciprofloxacin: metronidazole: minocycline to a final concentration of 0.1-1.0 mg/ml. Triple antibiotic paste has been associated with tooth discoloration. Double antibiotic paste without minocycline paste or substitution of minocycline for other antibiotic (e.g., clindamycin; amoxicillin; cefaclor) is another possible alternative as root canal disinfectant. Deliver into canal system via syringe If triple antibiotic is used, ensure that it remains below CEJ***** (minimize crown staining). Seal with 3-4mm of a temporary restorative material such as Cavit™, IRM™, glassionomer or another temporary material. Dismiss patient for 1-4 weeks.</p>
Second Appointment (1-4 weeks after 1st visit)	<p>Assess response to initial treatment. If there are signs/symptoms of persistent infection, consider additional treatment time with antimicrobial, or alternative antimicrobial. Anesthesia with 3% mepivacaine without vasoconstrictor, dental dam isolation. Copious, gentle irrigation with 20ml of 17% EDTA****. Dry with paper points. Create bleeding into canal system by over-instrumenting (endo file, endo explorer) (induce by rotating a pre-curved K-file at 2 mm past the apical foramen with the goal of having the entire canal filled with blood to the level of the cemento-enamel junction). An alternative to creating of a blood clot is the use of platelet-rich plasma (PRP), platelet rich fibrin (PRF) or autologous fibrin matrix (AFM). Stop bleeding at a level that allows for 3-4 mm of restorative material. Place a resorbable matrix such as CollaPlug™, Collacote™, CollaTape™ over the blood clot if necessary and white MTA** as capping material. A 3-4 mm layer of glass ionomer (e.g. Fuji IX™, GC America, Alsip, IL) is flowed gently over the capping material and light-cured for 40 s. MTA** has been associated with discoloration. Alternatives to MTA** (such as bioceramics or tricalcium silicate cements [e.g., Biodentine®, Septodont, Lancasted, PA, USA]) should be considered in teeth where there is an esthetic concern. o Anterior and Premolar teeth - Consider use of Collatape/Collaplug and restoring with 3mm of a nonstaining restorative material followed by bonding a filled composite to the beveled enamel margin. o Molar teeth or teeth with PFM***** crown - Consider use of Collatape/Collaplug and restoring with 3mm of MTA**, followed by RMGI*****, composite or alloy.</p>
Follow-up. Clinical and Radiographic exam	<ul style="list-style-type: none"> • No pain, soft tissue swelling or sinus tract (often observed between first and second appointments). • Resolution of apical radiolucency (often observed 6-12 months after treatment) • Increased width of root walls (this is generally observed before apparent increase in root length and often occurs 12-24 months after treatment). • Increased root length. • Positive Pulp vitality test response
Goals:	<p>Primary goal: The elimination of symptoms and the evidence of bony healing. Secondary goal: Increased root wall thickness and/or increased root length (desirable, but perhaps not essential) Tertiary goal: Positive response to vitality testing (which if achieved, could indicate a more organized vital pulp tissue)</p>

*** AAE - American Association of Endodontists
 * ASA - American Society of Anesthesiologists
 ***** CEJ - Cement Enamel Junction
 **** EDTA - Ethylenediaminetetraacetic acid
 ** MTA - Mineral Trioxide Aggregate
 ***** PFM - Preformed Metal
 ***** RMGI - Resin Modified Glass Ionomer

The revitalization procedure has a number of features that can complicate its implementation, especially for children. One of them is the inability to cause bleeding and the formation of a clot from periapical tissues, which eventually is to become a scaffold for tooth revitalization.

Objective

To describe alternative scaffold options for pulp revitalization, compare their effectiveness and describe possible causes of periapical tissues not bleeding during endodontic regenerative procedures

Materials and Methods

A comprehensive search strategy was done using PubMed (<https://pubmed.ncbi.nlm.nih.gov/>) and Cochrane Library (<https://www.cochranelibrary.com/>) databases in 1st of August 2023 by the using MESH terms equivalent to the keywords: regenerative endodontics, revascularization, immature permanent teeth, pediatric dentistry, literature review. Review articles for the last 5 years were found according to the keywords.

Exclusion criteria were following: articles describing animal and in vitro studies, clinical case reports, articles that do not describe scaffolding options for tooth revitalization, or comparisons of different scaffolding options, articles describing the revitalization of teeth with mature roots were excluded from the review, as well as those that include temporary teeth.

Results

According to the search criteria and keywords, 801 articles were found after applying the exclusion criteria, 11 were left that met the selection requirements.

Discussion

Approaches or regenerative procedures according to scaffold formation

Regeneration endodontics procedures (REPs) have been developed and considered as an alternative strategy for managing immature permanent teeth with pulpal necrosis, including cell-free and cell-based REPs

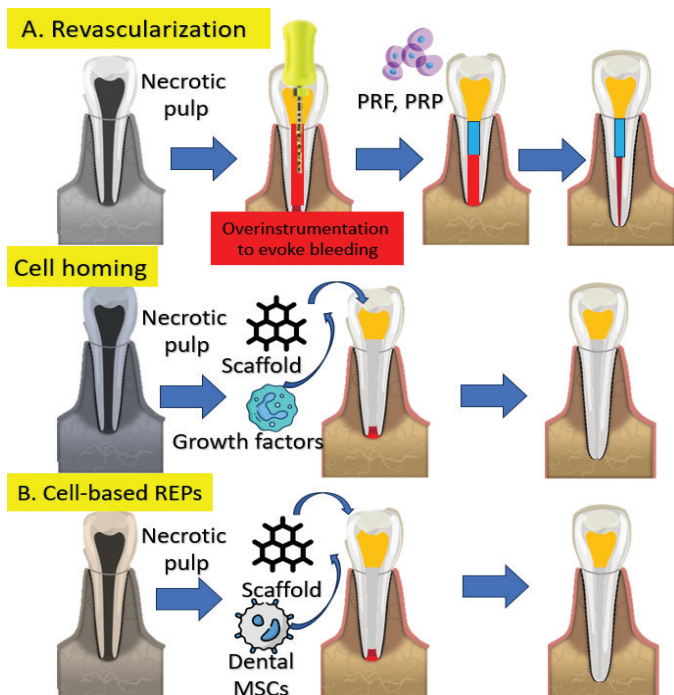


Figure 1. Schematic diagram of REPs. (A) Cell-free REPs. (B) Cell-based REPs [14]

Cell-free REPs include revascularization and cell homing options. Such approaches demonstrating prognostics periapical healing and continued root development [14]. However, the regenerated pulp-dentin complex is still absent in these cases. Dental MSCs, as one of the essentials of tissue engineering, are vital seed cells in regenerative medicine. Dental MSC-based REPs have presented promising potential with pulp-dentin regeneration in large animal studies and clinical trials via cell transplantation [14].

Cell-free REPs, including revascularization and cell homing with molecules recruiting endogenous MSCs, are successful in resolving apical periodontitis and arrested root formation, and widely applied in treating immature permanent teeth with necrotic pulp. Data obtained from histological researches demonstrates absence of pulp-dentin complex in such cases, even though some studies represents positive vitality testing results. Instead, cell-based REPs with dental MSCs have shown potential with pulp-dentin regeneration in large animal studies and clinical trials through cell transplantation. Before applying clinical transplantation of cell-based REPs, more research of isolation of stem cells, expansion of cells in vitro is necessary as well as, good practice facilities, skills of clinicians, training of assistants, and reduction of costs. It is hoped that when cell-based REPs provide true regeneration, they can be applied to the management of necrotic immature permanent teeth, resulting in long-term survival of patients' natural teeth and dentition.

Cell-based REPs show promising outcomes in pulp-dentin regeneration. Several cell-based REPs are at the stage of clinical studies [15, 16], but transplantation of stem cells is still not recommended by either the American Association of Endodontists (AAE) (2018) or the European Society of Endodontology (ESE) [17]. Multiple problems needed to be resolved before clinical application of stem cell transplantation [18]. MSCs are one of the most important elements in regenerative endodontics. However, their source and potency are still not fully used due to the limitation of our available knowledge [14].

Types of scaffolds for REPs of immature teeth

Different types of scaffolds which are used for REPs described in the literature. Among them there are both natural and synthetic ones. The analysis of scaffolds was assessed in reviews on pulp revascularization procedures of immature necrotic teeth. Different types of scaffolds were applied in a systematic way, namely blood clot and platelet-rich plasma (PRP) with and without collagen sponge [21], PRP with and without collagen [20–23], PRP and beta-tricalcium phosphate with and without hydroxyapatite [3], PRP with hydroxyapatite [24], PRP and bone, polyglycolid-poly(lactid) (PLGA) [3], platelet-rich fibrin (PRF) [13], blood clot with both PRP and PRF [24], PRF with and without blood clot, blood clot with collagen sponge or gelatin hydrogel and collagen calcium phosphate gel [20], platelet pellet [23], polymer fleece, bovine bone mineral [3], and empty scaffold [24]. All described scaffolds were clinically successful but so far there has been no meta-analytical evidence regarding any supplement providing better results for cell-based pulp/dentin regeneration than others [25].

As described above, a very promising direction is the use of stem cells for scaffold, on the other hand synthetic scaffolds developing has a number of advantages. Synthetic scaffolds have not limits regarding needed quantity and configuration, while natural scaffolds could be prepared only in limited number. This condition allows the acquisition of the scaffold in accordance with cell differentiation properties, certain pore characteristics, and certain mechanical, chemical, and degradation rate properties according to the desired application [26–28].

Synthetic polymer scaffolds

One of the directions in REPs and tissue engineering is development of polymer scaffolds as three-dimensional frame microenvironments that facilitate attachment, cellular infiltration, differentiation, proliferation, and stem cell metabolism with the aid of growth factors. Such a frame has to provide support for nutrition and oxygen diffusion in the regeneration process and should have biodegradable properties because it will be replaced by new tissue [29], [30]. Scaffold materials varies in means of their flexibility and degradability. Currently, natural or synthetic scaffolds have started to be commonly used in pulp tissue regeneration [31].

Several synthetic polymers have been developed, such as polyglycolic acid (PGA), poly(d,l-lactide-coglycolide) (PLGA), polylactic acid (PLA), poly(l-lactid) acid (PLLA), and polycaprolactone (PCL), and inorganic calcium phosphates, such as hydroxyapatite (HA) or beta-tricalcium phosphate (β TCP), as well as a combination of silica glass and phosphate. Synthetic scaffolds have been studied

considerably as the scaffolds that have the potential for tooth regeneration because of their nontoxicity, biodegradability, and ease with which to manipulate properties, including mechanical rigidity and degradation rate [32], [33]. In the future, it is hoped that more extensive research on various types of scaffolds can be carried out so that not only polymer-based scaffolds are described for the regeneration of dental pulp tissue [34].

Main types of scaffolds for clinical practice

Despite the interesting prospects of using stem cells and synthetic scaffolds for REP, currently procedures require further research, standardization of protocols, availability of materials. Instead, simplicity and accessibility of the procedure are important for everyday clinical practice, especially in pediatric dentistry. Based on the obtained results, it can be concluded that the main and most common method of scaffold formation in REPs, which meets the above-described requirements, is the blood clot formation [13, 19, 20, 35]. This is explained by the relative simplicity of the technique and the absence of additional materials' and instruments' necessity. At the same time, there are cases when it is impossible to cause sufficient bleeding to fill the cavity of the tooth and form a clot. Inadequate intra-canal bleeding has been identified as a challenge to successful REPs. Inability to provoke sufficient bleeding may be caused by significant periapical destruction area, pronounced inflammatory reaction on the applied dressing agent, and use of local anesthesia with epinephrine. [36]. Cases were described when, following the AAE protocol (use of an anesthetic without a vasoconstrictor), it was difficult to obtain a sufficient amount of blood to form a clot [37]. Another problem is the treatment of pulp necrosis of permanent molars with an unformed root, where irrigation could take a long time (according to the protocol). There are reviews in the literature that demonstrate the effectiveness of the revascularization technique in permanent molars [38], but there are some difficulties that may arise. Anesthetics based on 3% mepivacaine without vasoconstrictor have a shorter run and lower analgesic power than anesthetics with vasoconstrictor.

Over time, the effect of the local anesthetic weakens, and the resumption of pain sensitivity associated with it can significantly complicate the provocation of apical bleeding. The AAE protocol indicates that the alternative to creating a blood clot is the use of platelet-rich plasma (PRP), platelet rich fibrin (PRF) or autologous fibrin matrix (AFM).

Literature data consider that platelet-rich plasma (PRP), platelet-rich fibrin (PRF) and concentrated growth factor (CGF), can be a clinical alternative in REPs when intra-canal bleeding induction is unsuccessful [36, 39]. It is important to understand the clinical efficacy of alternative scaffolds for pulp regeneration and to compare clinical efficacy with each other and with a classic blood clot.

As we processed the literature, we discovered studies that demonstrated the root length increasing by 1.06 mm in the PRP group and 0.502 mm in the control group (blood clot formation), and the difference between groups was statistically significant. Conclusions summarize that procedures using autologous platelet concentrates contribute to the success of immature permanent teeth treatment, but the level of evidence was weak. The concentrates can be helpful, especially when there are problems with bleeding during the regenerative endodontic treatment. Autologous platelet concentrates can lead to development of the root and protect the tooth from extraction. However, more long-term clinical studies are needed [8]. The similar study that compared platelet concentrate scaffolds superior to traditional blood clot scaffolds showed next results. Compared with control teeth, teeth treated with PRP achieved better apical healing than blood clot group, and teeth treated with platelet concentrates showed improved apical closure, root lengthening, and thickening of the dentin walls, although these differences were not statistically significant. According to this platelet concentrates can be used as successful scaffolds for regenerative endodontic treatment of necrotic immature permanent teeth, and PRP as a scaffold may achieve better periapical healing of teeth with periapical inflammation, although they did not differ significantly from conventional blood clot scaffolds in development of the root [40]. Another study also compared efficacy

and differences in clinical effects of platelet-rich plasma (PRP) and platelet-rich fibrin (PRF), against blood clot revascularization (BCR) for the regeneration of immature permanent teeth. After 12 months revascularization outcomes were compared between groups: apical closure rate, a periapical lesion healing response, root lengthening, and dentinal wall thickening (Table 2) [41].

Table 2. The success rate of revascularization clinical effect after 1 year [41]

Scaffold type	Clinical Goals	Success rate of apical closure	Rate of root lengthening	Periapical lesion healing response	Dentinal wall thickening
Platelet-rich plasma (PRP)		85.1%	64.2%	100%	100%
Platelet-rich fibrin (PRF)		85.2%	74.1%	100%	100%
Blood clot revascularization (BCR)		58.8%	64.1%	88.9%	100%

According to analysis data, apical closure occurred more frequently after PRP and PRF than BCR; all the other effects of the PRP, PRF, and BCR treatments were similarly effective.

Another study analyzed similar results in scaffold formation such as dentinal wall thickness (DWT), increase in root length (RL), calcific barrier formation (CB), apical closure (AC), vitality response (VR), and success rate (SR). The results were similar and showed that APCs could be beneficial in terms of better apical closure and improved response to vitality tests when treating young, immature, necrotic, permanent teeth [23]. Next review compared blood clot, platelet-rich plasma, platelet-rich fibrin, and blood clots combined with different membranes such as collagen membrane, collagen membrane and placentex, chitosan membrane and hydrogel with basic growth factor for fibroblasts. The clinical success rate is excellent for all scaffolds used. The best scaffold for root development is platelet-rich plasma and it is the scaffold with the highest percentage of response to vitality test. The conclusion stated that platelet-rich plasma is the preferred scaffold of choice, although all the scaffolds analysed have acceptable results [42].

According to the studied materials, it is safe to say that platelet-rich plasma, platelet-rich fibrin, as alternative methods of scaffold forming for further revitalization, as effective as the blood clot formation. With preliminary preparation (blood sampling and centrifugation), they can be used in clinical practice, especially for children, in case of failure with the formation of a blood clot.

REPs protocols are being improved, comparative studies are being conducted, and this promising technique has already taken its place among more researched and established methods. The main criteria for the application of regenerative approaches at this stage is the stage of root formation (Figure 2).

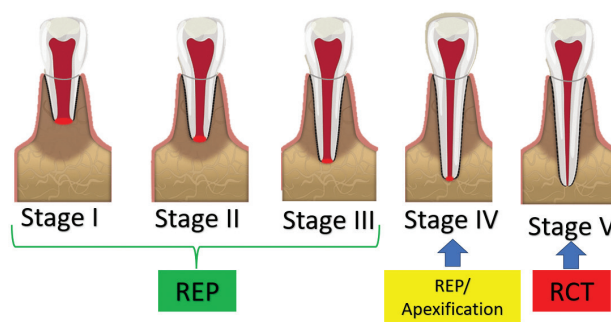


Figure 2. Stages of root formation by Cvek and recommendations regarding the type of endodontic intervention [36]

Conclusions

From the clinical point of view, the management of immature permanent teeth with necrotic pulp is a challenging clinical procedure. Traditionally, apexification was the first choice for dealing with these situations. However, REPs ground on three main objectives: apexification, to prevent or to heal the periapical tissues; the increase of length and thickness of the root, increasing the root resistance to fracture; and to regain pulp sensitivity. Overall, the available evidence points to the existence of clinical success in these three premises; however, the science behind the most appropriate clinical protocol remains to be explained.

REPs allow to solve problems that previously led to early loss of permanent teeth and significant dental problems for both adults and children. At the same time, REPs techniques are relatively simple to perform and do not require significant additional tools or materials, which is very important in pediatric dentistry.

Today, there is a wide variety of materials that are offered as a scaffold for pulp tissue regeneration, however, despite their advantages, they still have certain limitations in their application and require further research and improvement. The main method of obtaining such a scaffold is still the blood clot formation. However, if it is not possible to obtain bleeding from the periapical tissues for its formation, then the use of platelet-enriched autologous plasma or platelet-rich fibrin is recommended.

Conflict of Interest

The authors confirm absence of association with any organization or company that may have any financial or non-financial interest in the materials of research discussed in this article.

Funding

No funding was received to conduct this research.

References

- Cervino G, Laino L, D'Amico C, Russo D, Nucci L, Amoroso G, Gorassini F, Tepedino M, Terranova A, Gambino D, Mastroieni R. Mineral trioxide aggregate applications in endodontics: A review. *Eur J Dent.* 2020;14(04):683–91. doi: 10.1055/s-0040-1713073
- Duggal M, Tong HJ, Al-Ansary M, Twati W, Day PF, Nazzal H. Interventions for the endodontic management of non-vital traumatized immature permanent anterior teeth in children and adolescents: a systematic review of the evidence and guidelines of the European Academy of Paediatric Dentistry. *Eur Arch Paediatr Dent.* 2017;18(3):139–151. doi: 10.1007/s40368-017-0289-5
- Chisini LA, Grazioli G, Francia A, San Martin AS, Demarco FF, Conde MC. Revascularization versus apical barrier technique with mineral trioxide aggregate plug: A systematic review. *G Ital Endod.* 2018;32(1):9–16. doi:10.1016/j.gien.2018.03.006
- Murray PE. Review of guidance for the selection of regenerative endodontics, apexogenesis, apexification, pulpotomy, and other endodontic treatments for immature permanent teeth. *Int Endod J.* 2023;56:188–199. doi: 10.1111/iej.13809
- Murray PE, Garcia-Godoy F, Hargreaves KM. Regenerative Endodontics: A Review of Current Status and a Call for Action. *J Endod.* 2007;33:377–390. doi:10.1016/j.joen.2006.09.013
- Kaushik SN, Kim B, Cruz Walma AM, Choi SC, Wu H, Mao JJ, Jun HW, Cheon K. Biomimetic microenvironments for regenerative endodontics. *Biomater Res.* 2016;20:1–12. doi: 10.1186/s40824-016-0061-7
- Antunes LS, Salles AG, Gomes CC, Andrade TB, Delmindo MP, Antunes LAA. The effectiveness of pulp revascularization in root formation of necrotic immature permanent teeth: A systematic review. *Acta Odontol Scand.* 2016;74:161–169. doi: 10.3109/00016357.2015.1069394
- Metlerska J, Fagogeni I, Nowicka A. Efficacy of Autologous Platelet Concentrates in Regenerative Endodontic Treatment: A Systematic Review of Human Studies. *J Endod.* 2019;45:20–30.e1. doi:10.1016/j.joen.2018.09.003

- Nicoloso GF, Goldenfum GM, Dal Pizzol TDS, Scarparo RK, Montagner F, De Almeida Rodrigues J, Casagrande L. Pulp revascularization or apexification for the treatment of immature necrotic permanent teeth: Systematic review and meta-analysis. *J Clin Pediatr Dent.* 2019;43:305–313. doi: 10.17796/1053-4625-43.5.1
- AAE. AAE Clinical Considerations for a Regenerative Procedure Revised 2018. Available online: <https://www.aae.org/specialty/wp-content/uploads/sites/2/2017/06/currentregenerativeendodonticconsiderations.pdf>. Accessed on 7th of January 2021.
- Kontakiotis EG, Filippatos CG, Agrafioti A. Levels of evidence for the outcome of regenerative endodontic therapy. *J Endod.* 2014;40:1045–1053. doi:10.1016/j.joen.2014.03.013
- He L, Zhong J, Gong Q, Kim SG, Zeichner SJ, Xiang L, Ye L, Zhou X, Zheng J, Liu Y, Guan C. Treatment of necrotic teeth by apical revascularization: meta-analysis. *Sci Rep.* 2017;7(1):13941. doi:10.1038/s41598-017-14412-x
- Koç S, Del Fabbro M. Does the Etiology of Pulp Necrosis Affect Regenerative Endodontic Treatment Outcomes? A Systematic Review and Meta-analyses. *J Evid Based Dent Pract.* 2020;20:101400. doi: 10.1016/j.jebdp.2020.101400
- Cui D, Yu S, Zhou X, Liu Y, Gan L, Pan Y, Zheng L, Wan M. Roles of Dental Mesenchymal Stem Cells in the Management of Immature Necrotic Permanent Teeth. *Front Cell Dev Biol.* 2021;9:666186. doi: 10.3389/fcell.2021.666186.6/jebdp.2020.101400
- Nakashima M, Iohara K, Murakami M, Nakamura H, Sato Y, Arijii Y, Matsushita K. Pulp regeneration by transplantation of dental pulp stem cells in pulpitis: a pilot clinical study. *Stem Cell Res Ther.* 2017;8:1–3. doi: 10.1186/s13287-017-0506-5
- Xuan K, Li B, Guo H, Sun W, Kou X, He X, Zhang Y, Sun J, Liu A, Liao L, Liu S. Deciduous autologous tooth stem cells regenerate dental pulp after implantation into injured teeth. *Sci Transl Med.* 2018;10(455):eaaf3227. doi: 10.1126/scitranslmed.aaf3227.
- Galler KM, Krastl G, Simon S, Van Gorp G, Meschi N, Vahedi B, Lambrechts P. European Society of Endodontology position statement: Revitalization procedures. *Int Endod J.* 2016;49(8):717–23. doi: 10.1111/iej.12629
- Huang GT, Al-Habib M, Gauthier P. Challenges of stem cell-based pulp and dentin regeneration: A clinical perspective. *Endod Topics.* 2013;28(1):51–60. doi: 10.1111/etp.12035
- Kharchi AS, Tagiyeva-Milne N, Kanagasingam S. Regenerative endodontic procedures, disinfectants and outcomes: A systematic review. *Prim Dent J.* 2020;9(4):65–84. doi:10.1177/2050168420963302
- Torabinejad M, Nosrat A, Verma P, Udochukwu O. Regenerative endodontic treatment or mineral trioxide aggregate apical plug in teeth with necrotic pulps and open apices: a systematic review and meta-analysis. *J Endod.* 2017;43(11):1806–20. doi: 10.1016/j.joen.2017.06.029
- Lolato A, Bucchi C, Taschieri S, Kabbaney AE, Del Fabbro M. Platelet concentrates for revitalization of immature necrotic teeth: A systematic review of the clinical studies. *Platelets.* 2016;27:383–392. doi: 10.3109/09537104.2015.1131255
- Ong TK, Lim GS, Singh M, Fial AV. Quantitative Assessment of Root Development after Regenerative Endodontic Therapy: A Systematic Review and Meta-Analysis. *J Endod.* 2020;46:1856–1866.e2. doi: 10.1016/j.joen.2020.08.016
- Panda S, Mishra L, Arbildo-Vega HI, Lapinska B, Lukomska-Szymanska M, Khijmatgar S, Parolia A, Bucchi C, Del Fabbro M. Effectiveness of Autologous Platelet Concentrates in Management of Young Immature Necrotic Permanent Teeth—A Systematic Review and Meta-Analysis. *Cells.* 2020;9:2241. doi: 10.3390/cells9102241
- Alghamdi FT, Alqurashi AE. Regenerative Endodontic Therapy in the Management of Immature Necrotic Permanent Dentition: A Systematic Review. *Sci World J.* 2020;2020:7954357. doi: 10.1155/2020/7954357
- Lopes LB, Neves JA, Botelho J, Machado V, Mendes JJ. Regenerative Endodontic Procedures: An Umbrella Review. *Int J Environ Res Public Health.* 2021;18:754. doi:10.3390/ijerph18020754
- Sharma S, Srivastava D, Grover S, Sharma V. Biomaterials in tooth tissue engineering: A review. *J Clin Diagn Res.* 2014;8:309–315. doi: 10.7860/JCDR/2014/7609.3937
- Suamte L, Tirkey A, Babu PJ. Design of 3D smart scaffolds using natural, synthetic and hybrid derived polymers for skin regenerative applications. *Smart Mater Med.* 2023;4:243–256. doi:10.1016/j.smaim.2022.09.005

28. Tran TT, Hamid ZA, Cheong KY. A Review of Mechanical Properties of Scaffold in Tissue Engineering: Aloe Vera Composites. *J Phys Conf Ser.* 2018;1082:012080. doi: 10.1088/1742-6596/1082/1/012080
29. Srivastava S. Current and future perspectives for dentin-pulp tissue engineering - An update. *S Afr Dent J.* 2019;74:110–114. doi: org/10.17159/2519-0105/2019/v74no3a1
30. Dang M, Saunders L, Niu X, Fan Y, Ma PX. Biomimetic delivery of signals for bone tissue engineering. *Bone Res.* 2018;6:25. doi: 10.1038/s41413-018-0025-8
31. Xie Z, Shen Z, Zhan P, Yang J, Huang Q, Huang S, Chen L, Lin Z. Functional dental pulp regeneration: Basic research and clinical translation. *Int J Mol Sci* 2021;22:8991. doi: 10.3390/ijms22168991
32. Moussa DG, Aparicio C. Present and future of tissue engineering scaffolds for dentin-pulp complex regeneration. *J Tissue Eng Regen Med.* 2019;13:58–75. doi: 10.1002/term.2769
33. Noohi P, Abdekhodaie MJ, Nekoofar MH, Galler KM, Dummer PMH. Advances in scaffolds used for pulp-dentine complex tissue engineering: A narrative review. *Int Endod J.* 2022;55(12):1277–1316. doi: 10.1111/iej.13826
34. Sugiaman VK, Jeffrey, Naliani S, Pranata N, Djuanda R, Saputri RI. Polymeric Scaffolds Used in Dental Pulp Regeneration by Tissue Engineering Approach. *Polymers.* 2023;15(5):1082. <https://doi.org/10.3390/polym15051082>
35. Caviedes-Bucheli J, Muñoz-Alvear HD, Lopez-Moncayo LF, Narvaez-Hidalgo A, Zambrano-Guerrero L, Gaviño-Orduña JF, Portigliatti R, Gomez-Sosa JF, Munoz HR. Use of scaffolds and regenerative materials for the treatment of immature necrotic permanent teeth with periapical lesion: Umbrella review. *Int Endod J.* 2022;55(10):967–88. doi: 10.1111/iej.13799.
36. Wei X, Yang M, Yue L, Huang D, Zhou X, Wang X, Zhang Q, Qiu L, Huang Z, Wang H, Meng L. Expert consensus on regenerative endodontic procedures. *Int J Oral Sci.* 2022;14(1):55. doi: 10.1038/s41368-022-00206-z.
37. Staffoli S, Plotino G, Nunez Torrijos BG, Grande NM, Bossù M, Gambarini G, Polimeni A. Regenerative Endodontic Procedures Using Contemporary Endodontic Materials. *Materials (Basel).* 2019;12(6):908. doi: 10.3390/ma12060908
38. Tzanetakis GN, Giannakoulas DG, Papanakou S, Gizani S, Lygidakis N. Regenerative endodontic therapy of immature permanent molars with pulp necrosis: a cases series and a literature review. *Eur Arch Paediatr Dent.* 2021;22(3):515–525. doi: 10.1007/s40368-020-00550-w.
39. Kim SG, Malek M, Sigurdsson A, Lin LM, Kahler B. Regenerative endodontics: a comprehensive review. *Int Endod J.* 2018;51(12):1367–1388. doi: 10.1111/iej.12954
40. Tang Q, Jin H, Lin S, Ma L, Tian T, Qin X. Are platelet concentrate scaffolds superior to traditional blood clot scaffolds in regeneration therapy of necrotic immature permanent teeth? A systematic review and meta-analysis. *BMC Oral Health.* 2022;22(1):589. doi: 10.1186/s12903-022-02605-4.
41. Murray PE. Platelet-Rich Plasma and Platelet-Rich Fibrin Can Induce Apical Closure More Frequently Than Blood-Clot Revascularization for the Regeneration of Immature Permanent Teeth: A Meta-Analysis of Clinical Efficacy. *Front Bioeng Biotechnol.* 2018;6:139. doi: 10.3389/fbioe.2018.00139.
42. Pecci-Lloret MP, Nandin-Muttoni G, Pecci-Lloret MR, Guerrero-Gironés J, Rodríguez-Lozano FJ. Scaffolds for pulp revitalisation: A systematic review of randomized clinical trials. *Ann Anat.* 2022;243:151936. doi: 10.1016/j.aanat.2022.151936.
43. Eramo S, Natali A, Pinna R, Milia E. Dental pulp regeneration via cell homing. *Int Endod J.* 2018;51:405–419. doi: doi.org/10.1111/iej.12868
44. Altaii M, Richards L, Rossi-Fedele G. Histological assessment of regenerative endodontic treatment in animal studies with different scaffolds: A systematic review. *Dent Traumatol.* 2017;33:235–244. doi: 10.1111/edt.12338

Регенеративна ендодонтія: типи каркасів та їх переваги для дитячої стоматології

Олег Ковнацький ^{A, B, C, D}
DMD, Приватна практика, Київ, Україна
ORCID ID: 0009-0000-8188-4319

Станіслав Геранін ^{E, F}
PhD, Department of Dentistry, V. N. Karazin Kharkiv National, Kharkiv, University Ukraine
ORCID ID: 0000-0002-4266-9189

Відповідальний автор для листування: Олег Ковнацький: проспект Алішера Навої 69, 258, Київ, 02130 Україна
E-mail: kovnatskyioleg@gmail.com

A – розробка концепції та дизайну дослідження, B – збір та або систематизація даних дослідження, C – аналіз та тлумачення даних дослідження, D – написання публікації,
E – критичне доопрацювання тексту публікації, F – остаточне затвердження.

Стаття:

Історія статті:
Надійшла до редакції 6 серпня 2023
Прийнята до друку 22 серпня 2023
Доступна онлайн 11 грудня 2023

Ключові слова:
каркас пульпи, регенеративна ендодонтія, регенерація пульпи зуба, реваскуляризація пульпи, незрілі постійні зуби, дитяча стоматологія, огляд літератури

Анотація

Вступ. Регенеративні ендодонтичні процедури (РЕП) забезпечують сприятливе середовище для природної регенерації/репарації стінки кореня з збереженням функціонуєчого комплексу пульпи та дентину а також формують умови для завершення формування ділянки апексу. Проте РЕП характеризуються певними особливостями реалізації, які можуть ускладнити процес їх виконання, особливо у пацієнтів дитячого віку, однією з яких є формування належного каркасу для регенерації.

Мета. Описати альтернативні варіанти формування каркасу для ревіталізації пульпи, порівняти їхню ефективність, а також описати можливі причини відсутності кровотечі з ділянки периапікальних тканин під час виконання ендодонтичних регенеративних процедур.

Матеріали та методи. Комплексна стратегія пошуку була проведена через бази даних PubMed і Cochrane Library з використанням термінів MESH, які були підібрані як еквіваленти основним ключовим словам. Для аналізу приймалися оглядові статті, опубліковані в період останніх 5 років, відбір котрих проводився за ключовими словами та з використанням критеріїв виключення.

Результати. З використанням критеріїв пошуку та у відповідності до ключових слів було сформовано пул із 801 публікації, з яких після застосування критеріїв виключення лише 11 були використані для деталізованого аналізу, як такі які відповідали вимогам відбору.

Висновки. Основним способом отримання каркасу для регенерації є формування кров'яного згустка. Однак, при неможливості індукції кровотечі з ділянки периапікальних тканин рекомендується використовувати аутологічну плазму або ж фібрин, збагачені тромбоцитами. Дана техніка характеризується ефективністю аналогічною результату індукції кровотечі з периапікальних тканин. Крім того, використання плазми або ж фібрину, збагачених тромбоцитами, дозволяє уникнути больових відчуттів, які можуть виникати в ході провокування кровотечі для утворення кров'яного згустка.

Заява про конфлікт інтересів

Цим автори підтверджують відсутність зв'язку з будь-якою організацією чи компанією, яка може мати будь-який фінансовий або нефінансовий інтерес до матеріалів дослідження, розглянутих в цій статті.

Заява про фінансування

Не було отримано жодного фінансування для допомоги в підготовці та проведенні цього дослідження, а також для написання цієї статті.

<https://doi.org/10.56569/UDJ.2.2.2023.107-113>
2786-6572/© 2023 The Author(s).